

Sclerosing stromal tumour of the ovary.

Ranjini Kudva, K. Ramnarayan, Ravikala Rao, Prahlad Kushtagi,

Departments of Pathology, Obstetrics & Gynaecology, Kasturba Medical College, Manipal.

Sclerosing stromal tumour of the ovary is a rare benign tumour of ovarian stromal origin. It forms a distinct subgroup by virtue of its unique histologic features. One such tumour in a 40 yr old female is reported.

A 40 year old female presented with irregular bleeding per vaginum associated with pain in the right iliac fossa for 3 years. Vaginal examination revealed normal sized uterus with a 6 x 7 cm firm regular mass in the anterior fornix. Ultrasound scan revealed a solid 7.5 cm mass with echolucent small areas on the right side of uterus. Right ovary was not visualized. Left ovary was normal. A clinical diagnosis of broad ligament fibroid or ovarian tumour was made and was posted for laparotomy. During surgery the right ovary was enlarged 6 x 8 cm solid with cystic areas. Capsule was intact. Uterus, left ovary and tubes were normal. Abdominal Panhysterectomy was performed. The post-operative period was uneventful.

On examination right ovary showed a grey white lobulated firm tumour 8 x 6 cm with yellowish, mucoid and haemorrhagic areas. On histological examination, the tumour was characterised by lobular pattern of cellular zones, fibrous and oedematous areas. The cellular area showed round cells with vesicular nuclei, prominent nucleoli and clear to eosinophilic cytoplasm. Also seen were vacuolated cells with eccentric nuclei simulating signet ring cells. The vacuoles contained lipid and not mucin. Features were supportive of sclerosing stromal tumour.

Sclerosing stromal tumour is a rare ovarian tumour of stromal origin, originally differentiated from other sex cord, stromal tumours by Chalvardjian and Scully (1973) and later by Damjanov et al (1975). Sclerosing stromal tumour occurs in a younger age group. This tumour is char-

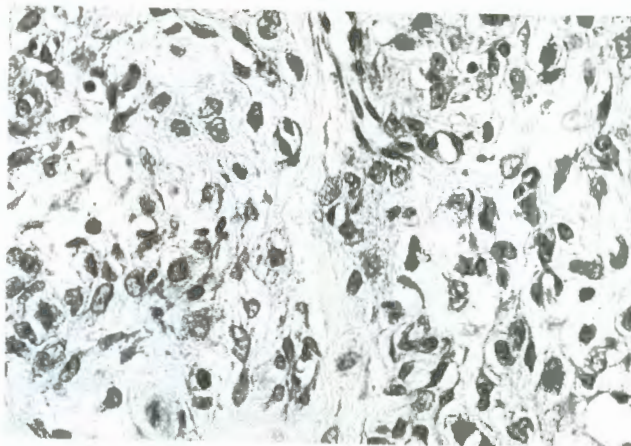


Fig. I. Sectioned surface of tumour is grey white with pseudolobulation

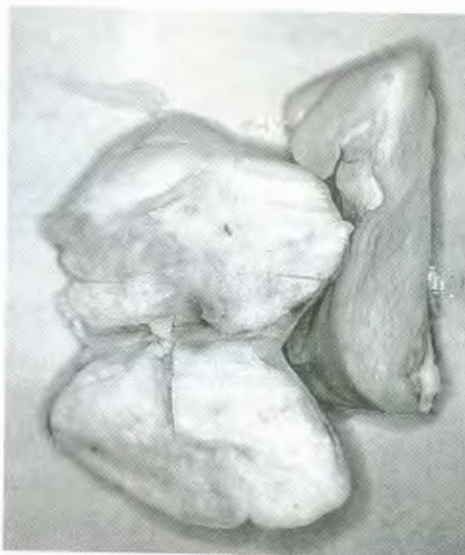

Fig II Cellular area of tumour in which many of tumour cells resemble signet ring cells. H x E x 300.

acterised by spindle cells and lipid containing round or oval cells. Some of the latter may have a signet ring appearance and thus simulate a Krukenberg tumour. All sclerosing stromal tumour have to date, pursued a benign course, local excision is adequate therapy.